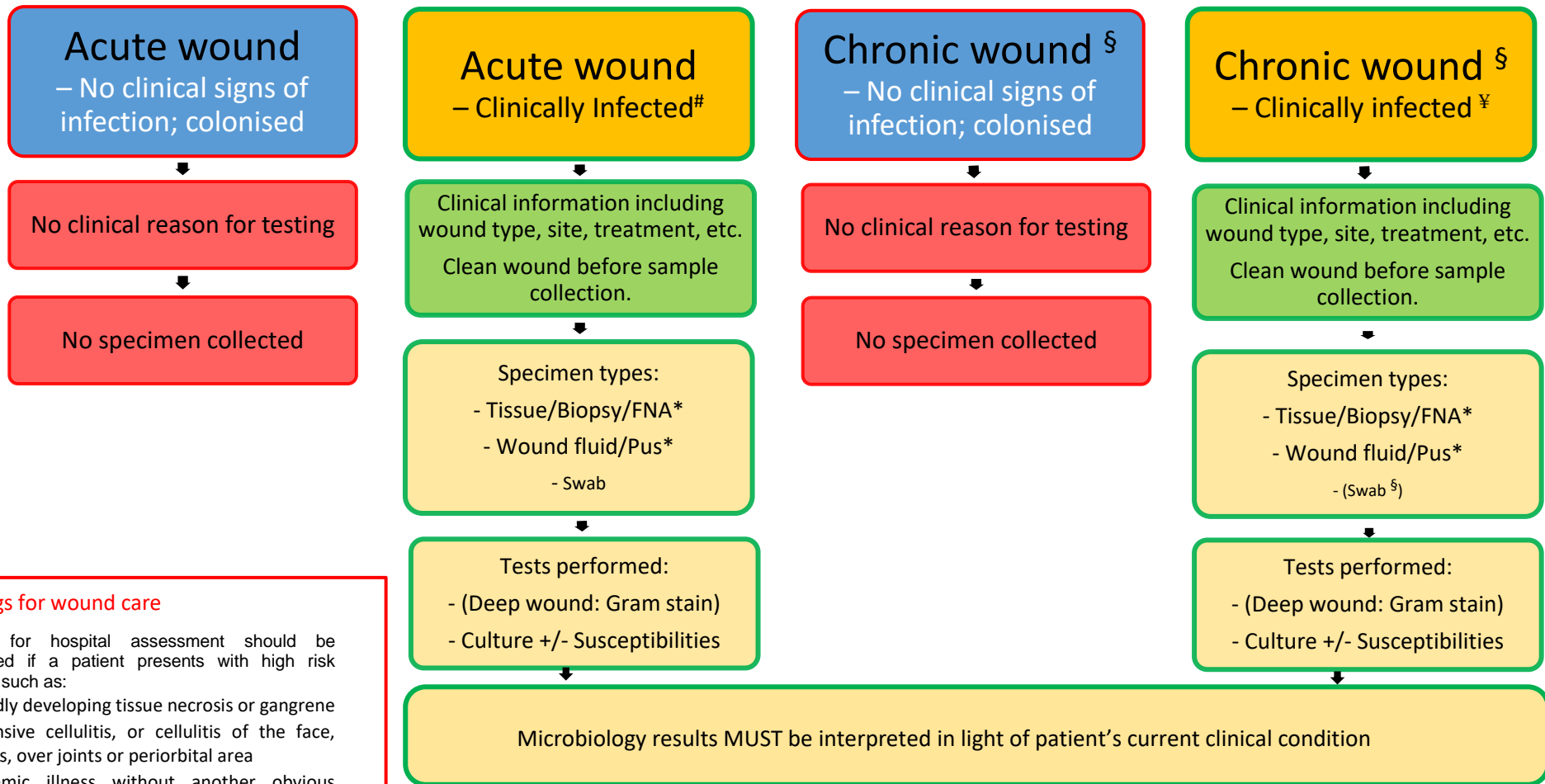


WOUND SWAB LABORATORY TESTING GUIDE



Red flags for wound care

Referral for hospital assessment should be considered if a patient presents with high risk features, such as:

- Rapidly developing tissue necrosis or gangrene
- Extensive cellulitis, or cellulitis of the face, hands, over joints or periorbital area
- Systemic illness without another obvious cause
- Clinical signs suggestive of osteomyelitis, e.g. deep bone pain, fever or chills
- Pain unrelieved by analgesics such as paracetamol or codeine
- A non-healing or worsening wound in a patient with diabetes

Classic Clinical Signs – Acute:

- New or increased pain
- Swelling
- Erythema
- Purulent exudate
- Localised warmth around the site of infection

§ The surface of **chronic lesions** are often colonised with enteric or other flora. Superficial **swabs from such sites are generally unhelpful** when making wound management decisions.

*Recommended specimen.

¥ Clinical Signs – Chronic:

(Also see Classic Clinical Signs – Acute #)

- Discolouration of granulation tissue
- “Foamy” granulation tissue
- Contact bleeding
- Tissue breakdown (particularly new tissue)
- Epithelial bridging